

Surgical Outcomes of Congenital Upper Eyelid Coloboma at Tertiary Care Hospital



Murtaza Sameen Junejo¹, Amna Manzoor², Saadullah³, Fariha Taimur⁴, Sumeya Ali Khan⁵
¹⁻⁵*Al-Shifa Trust Eye Hospital, Rawalpindi*

ABSTRACT

Purpose: To observe surgical outcomes of patients with congenital upper eyelid coloboma.

Study Design: Retrospective case series.

Place and Duration of Study: Armed Forces institute of Ophthalmology from April 2023 to July 2023.

Methods: A total of 06 patients who underwent surgical closure of congenital upper eyelid coloboma (CEC) were included. The data was collected from the record room of Armed Forces Institute of Ophthalmology. A Tenzel semicircular flap technique was performed to close the defects. Data analysis was done with SPSS version 22.0.

Results: Out of six patients with upper eyelid coloboma, five (83.3%) were males and one (16.7%) was female. The mean age was 20.3 ± 5.2 months. Direct closure with cantholysis was performed in the right eye of two (33.3%) patients, while four (66.7%) patients underwent repair of the left eye using a Tenzel semicircular flap. Successful outcomes were achieved in five (83.3%) patients. One patient (16.7%) required redo surgery due to wound dehiscence, which occurred because of increased skin tension during childhood growth.

Conclusion: Surgical repair of congenital upper eyelid coloboma using direct closure with cantholysis for smaller defects and the Tenzel semicircular flap for larger defects provides favorable functional and cosmetic outcomes. In this series, the majority of patients achieved successful eyelid reconstruction, with only one case requiring redo surgery due to wound dehiscence. These findings suggest that appropriate selection of surgical technique based on defect size is effective for the management of congenital upper eyelid coloboma.

Keywords: Congenital coloboma, eyelid coloboma, eyelid defect.

How to Cite this Article: Junejo MS, Manzoor A, Saadullah, Taimur F, Khan SA. Surgical Outcomes of Congenital Upper Eyelid Coloboma at Tertiary Care Hospital. 2026;42(2):156-160. [Doi:10.36351/pjo.v42i2.2323](https://doi.org/10.36351/pjo.v42i2.2323)

*Correspondence to: Murtaza Sameen Junejo
Al-Shifa Trust Eye Hospital, Rawalpindi
Email: drmurtazasameen@gmail.com*

Received: December 27, 2025

Revised: March 15, 2026

Accepted: March 19, 2026

INTRODUCTION

Congenital eyelid coloboma is a rare abnormality, in which there is partial or complete lid defects involving both anterior and posterior lamella.¹ It results from failure of fusion of mesodermal folds and can be unilateral or bilateral, sometimes occurring in isolation and sometimes associated with other ocular, auditory or systemic anomalies. They have been associated with approximately 27 syndromes, most of them are

derived from 1st arch syndromes namely Goldenhar and Treacher Collin.² Various different causes have been discussed in literature, among which maternal Vitamin A deficiency, toxoplasmosis, cytomegalovirus and thalidomide have been mostly the discussed etiologies.^{3,4}

It has been observed that the prevalence of coloboma is 2 to 14 per 100000 births.⁵ A multidisciplinary team is required to manage such patients, as most of the colobomas occur in association with other systemic abnormalities.^{6,7}

Eyelid colobomas are divided into three categories: lid defects involving less than 25% of the lid are considered mild, 25-50% are moderate and more than 50% are larger defects.⁸

Mild lid defects are either observed with lubrication and moistchambers to delay surgery or

reconstructed with direct closure techniques. Rehabilitation of moderate defects requires lateral canthotomy and cantholysis either alone or in combination with Tenzel semicircular flaps. While larger defects require lid sharing techniques.⁹ The timing of surgery depends on the size of eyelid defects. Upper lid colobomas are more prone to sight threatening due to exposure keratopathy and conjunctival xerosis.¹⁰ This article aims to share the surgical outcomes of congenital upper eyelid colobomas at Armed Forces Institute Of Ophthalmology from 2020 to 2023.

METHODS

This retrospective study was conducted at Armed Forces institute of Ophthalmology from April 2023 to July 2022 after approval from hospital ethical review committee (Reference number 320/ERC/AFIO). Patients with eyelid colobomas involving 25 to 50% of the lid margin were included in this study. After complete history and ocular examination, location of the eyelid coloboma was noted. Conjunctival adhesions were also checked by lifting the eyelid defect. All colobomas were located in upper eyelid medially. Surgical closure was done either by direct closure or by Tenzel semicircular flaps with or without lateral canthotomy under general anaesthesia. Lid margin defect was aligned at grey line with 5/0 vicryl suture plus 6/0 silk suture and after dissecting the tissue at margins, both anterior and posterior lamella were sutured. Follow-up was done after 24 hours to see the anatomy, functioning and cosmesis of the eyelid defect. Statistical analysis was done with SPSS version 22.0. Frequency and percentage were calculated for categorical variables.

RESULTS

A total of 06 patients were included in this study. Out of 06 patients 05 (83.3%) were males and 01 (16.6%) was female. The mean age in months was 20.3 ± 5.2 . Direct closure with cantholysis was done in the right eye of 02 (33.3%) patients while Tenzel semicircular flap was performed in the left eye of 04 (66.6%) patients. Success was seen in 05 (83.3%) patients after a follow up period of 06 months, while in one (16.6%) patient wound dehiscence occurred due to excessive tension on the wound. All patients underwent single stage procedure except one which required wound approximation again with the help of Tenzel semicircular flap.

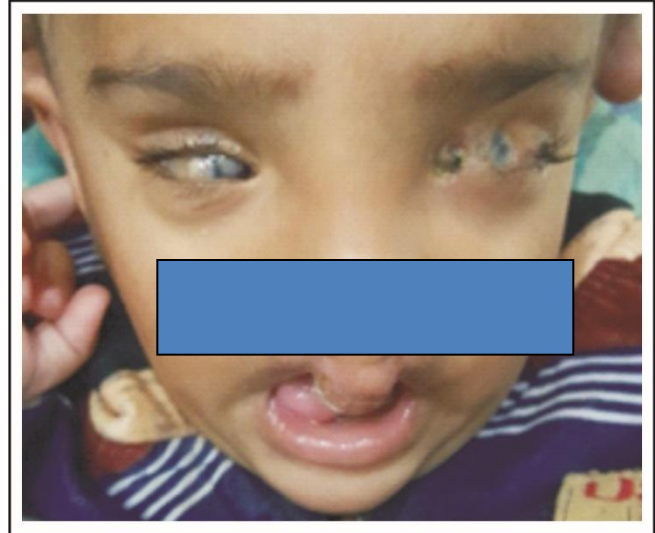

Fig. 1: Left Upper eyelid Coloboma (Goldenhar Syndrome).

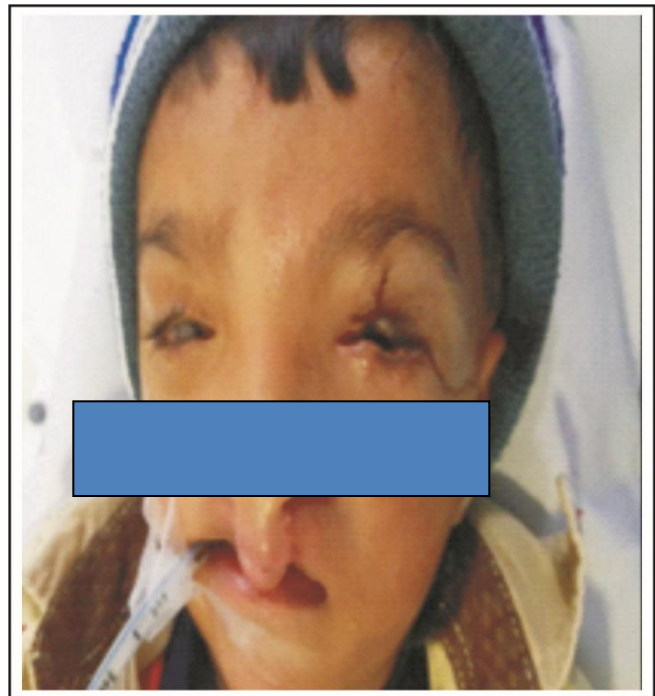

Fig. 2: Immediate Post Operative (After Tenzel Semicircular flap).

DISCUSSION

Orbito-maxillary clefts, cranio-facial and lateral facial clefts are less common clefts compared to cleft lip disorder.^{10,11} The incidence of these cranio-facial clefts is not clearly known; however, the literature estimates it to be between 1.4 and 6 per 100,000 live births.¹² There is an increased risk of damage to ocular surface if congenital upper eyelid coloboma is not

treated at appropriate time. The rate of exposure keratopathy increases if the defect remains unaddressed for longer duration. The chance of globe injuries in children increases and finally the most important reason for repair of such coloboma is disfigurement, which needs to be corrected to prevent child from psychological trauma.

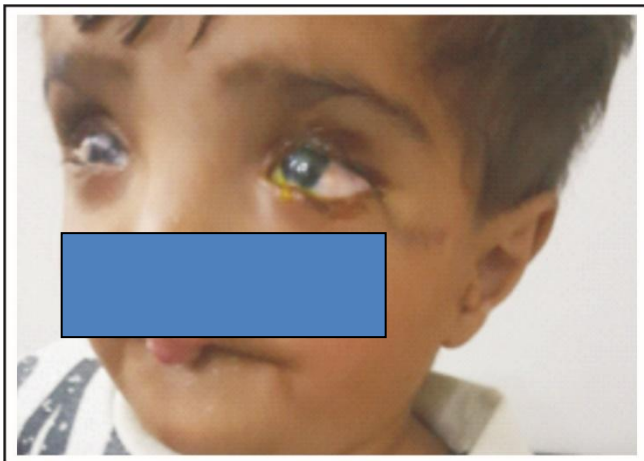


Fig. 3: After 4 weeks.

Eyelid repair with Tenzel semicircular flap and reverse Tenzel semicircular flap is also found in literature.^{13,14} We also used reverse Tenzel semicircular flap techniques in one of our cases due to shortened and tightened eyelid of the subject. Mostly mild to moderate eyelid coloboma are repaired with either direct closure or accompanying procedures like canthotomy and cantholysis. Tenzel semicircular flap techniques and reverse Tenzel semicircular flap techniques were used in our study for better cosmesis and functioning of eyelid and also to protect eyelid margin contour along with eyelashes. Hashish and Awara, in their study did one stage procedure for larger eyelid defects and they also used prepuce skin with acceptable cosmesis.¹⁵

Various techniques for eyelid reconstruction have been described in the literature. Direct closure and the Tenzel semicircular flap are most commonly employed for mild to moderate eyelid defects. Other reconstructive options include the Cutler–Beard procedure, Mustardé cheek rotation flap, composite grafts (from the contralateral eyelid or donor tissue), the Hughes tarsoconjunctival procedure, and lid-switch techniques, which are generally reserved for larger or more complex defects.^{16,17,18}

A recent advancement like tail flap technique has been introduced as a modification of Tenzel semicircular flap and McGregor flap.^{19,20} However, the long-term results are not available.

After a close follow up of such patients, a good cosmesis has been observed in patients undergoing repair with Tenzel semicircular flap along with cantholysis. In our study success was seen in 83.3% patients while in one (16.6%) subject wound dehiscence occurred who was repaired again with Tenzel semicircular technique.

A meticulous approach needs for upper eyelid coloboma reconstruction. Advantages of direct closure and Tenzel semicircular flaps is that they are ideal for eccentric lid defects and provide approximation of eyelashes with freely movable eyelids.

The study has several limitations. The small sample size and single-center retrospective design limit the generalizability of the findings. The short study duration and limited follow-up may not adequately capture long-term functional and cosmetic outcomes or late complications such as lid notching, lagophthalmos, or recurrence of wound dehiscence with facial growth. In addition, the absence of a comparative control group and the use of two different surgical techniques in a small cohort make it difficult to directly compare the effectiveness of each method. Larger prospective studies with longer follow-up are required to validate these findings and better define optimal surgical approaches for congenital upper eyelid coloboma.

CONCLUSION

Reconstruction of congenital upper eyelid coloboma using direct closure with cantholysis for smaller defects and the Tenzel semicircular flap for larger defects results in satisfactory functional and cosmetic outcomes. In this series, successful eyelid reconstruction was achieved in most patients, with only one case requiring repeat surgery due to wound dehiscence. These results indicate that selecting the surgical technique according to the size of the defect is an effective approach in the management of congenital upper eyelid coloboma.

Funding: This study was not funded by any organization.

Patient's Consent: Researchers followed the guidelines set forth in the Declaration of Helsinki.

Conflict of Interest: Authors declared no conflict of interest.

Ethical Approval: The study was approved by the Institutional review board/Ethical review board (320/ERC/AFIO)

REFERENCES

1. **Al-Essa D, Khandekar R, Galindo-Ferreiro A, Edward DP, Maktabi A, Al-Hussein H, et al.** Clinical and histological features and outcomes of upper eyelid colobomas in the Saudi population. *Orbit*. 2020;**39(5)**:325-330. Doi: 10.1080/01676830.2019.1690006.
2. **Johnson JM, Moonis G, Green GE, Carmody R, Burbank HN.** Syndromes of the first and second branchial arches, part 1: embryology and characteristic defects. *AJNR Am J Neuroradiol*. 2011;**32(1)**:14-19. Doi: 10.3174/ajnr.A2072.
3. **Chiummariello S, Angelisanti M, Arleo S, Alfano C.** Surgical treatment of upper eyelid coloboma: our experience. *Ann Ital Chir*. 2012;**83(5)**:379-383. PMID: 23064297.
4. **Yoo YJ, Han SB, Yang HK, Hwang JM.** Ocular coloboma combined with cleft lip and palate: a case report. *BMC Ophthalmol*. 2020;**20(1)**:418. Doi: 10.1186/s12886-020-01696-3.
5. **Skalicky SE, White AJ, Grigg JR, Martin F, Smith J, Jones M, et al.** Microphthalmia, anophthalmia, and coloboma and associated ocular and systemic features: understanding the spectrum. *JAMA Ophthalmol*. 2013;**131(12)**:1517-1524. Doi: 10.1001/jamaophthalmol.2013.5305.
6. **Hsu P, Ma A, Wilson M, Williams G, Curotta J, Munns CF, et al.** CHARGE syndrome: a review. *J Paediatr Child Health*. 2014;**50(7)**:504-511. Doi: 10.1111/jpc.12497.
7. **Sharma R, Sharma B, Babber M, Singh S, Jain G.** Treacher Collins syndrome: A case report and review of ophthalmic features. *Taiwan J Ophthalmol*. 2016;**6(4)**:206-209. Doi: 10.1016/j.tjo.2016.07.002.
8. **Kanukollu VM, Blair K, Ahmad SS.** Eyelid Coloboma. [Updated 2024 Feb 12]. In: StatPearls [Internet]. Treasure Island (FL): StatPearls Publishing; 2026 Jan-. Available from: <https://www.ncbi.nlm.nih.gov/books/NBK558905/>. Accessed: March 12, 2026
9. **Ortega Molina JM, Mora Horna ER, Salgado Miranda AD, Rubio R, Solans Pérez de Larraya A, Salcedo Casillas G.** Congenital Upper Eyelid Coloboma: Clinical and Surgical Management. *Case Rep Ophthalmol Med*. 2015;**2015**:286782. Doi: 10.1155/2015/286782.
10. **Krueger LA, Morris AC.** Eyes on CHARGE syndrome: Roles of CHD7 in ocular development. *Front Cell Dev Biol*. 2022;**10**:994412. Doi: 10.3389/fcell.2022.994412
11. **Das D, Modaboyina S, Agrawal S, Pushker N, Meel R, Bajaj MS.** Tessier cranio-facial clefts presenting to a tertiary eye care center in Northern India: Ophthalmic features and a review of management. *Indian J Ophthalmol*. 2022;**70(7)**:2552-2558. Doi: 10.4103/ijo.IJO_86_22.
12. **Kalantar-Hormozi A, Abbaszadeh-Kasbi A, Goravanchi F, Davai NR.** Prevalence of Rare Craniofacial Clefts. *J Craniofac Surg*. 2017;**28(5)**:e467-e470. Doi: 10.1097/SCS.0000000000003771.
13. **Abbasi S, Kamil Z, Faisal SM, Saad SM, Khan TH.** Upper Eyelid Reconstruction Surgeries; Comparison Of Outcomes Between Reverse Tenzel Flap Versus Cutler Beard Flap Procedure. *J Ayub Med Coll Abbottabad*. 2022;**34(1)**:36-40. Doi: 10.55519/JAMC-01-9045.
14. **Boesoirie SF, Dahlan MR, Kartiwa A, Ayu NP, Choi WC.** Modified versus conventional Tenzel semicircular flap in congenital bilateral upper eyelid colobomas occurring as an isolated finding: a case series. *J Cosmet Med*. 2020;**4(2)**:85-88. Doi: 10.25056/JCM.2020.4.2.85
15. **Hashish A, Awara AM.** One-stage reconstruction technique for large congenital eyelid coloboma. *Orbit*. 2011;**30(4)**:177-179. Doi:10.3109/01676830.2011.582979
16. **Khalid M, Moin M, Latif MA.** Reconstruction of congenital lid defects. *Pak J Ophthalmol* 2013;**29**:231-234. Doi: 10.36351/pjo.v29i04
17. **Tawfik HA, Abdulhafez MH, Fouad YA.** Congenital upper eyelid coloboma: embryologic, nomenclatorial, nosologic, etiologic, pathogenetic, epidemiologic, clinical, and management perspectives. *Ophthalmic Plast Reconstr Surg*. 2015;**31(1)**:1-12. Doi: 10.1097/IOP.0000000000000347.
18. **Cha JA, Lee KA.** Reconstruction of periorbital defects using a modified Tenzel flap. *Arch Craniofac Surg*. 2020;**21(1)**:35-40. Doi: 10.7181/acfs.2019.00577.
19. **Li C, Marles SL, Greenberg CR, Chodirker BN, van de Kamp J, Slavotinek A, et al.** Manitoba Oculotrichoanal (MOTA) syndrome: report of eight new cases. *Am J Med Genet A*. 2007;**143A(8)**:853-857. Doi: 10.1002/ajmg.a.31446.
20. **Haider G, Kadir SM, Mitra MR, Hossain T.** Tail flap for eyelid reconstruction: An alternative to Tenzel Flap. *Int Res J Optha*. 2021;**3**:21-28. Doi:10.36811/irjo.2021.110011

Authors Designation and Contribution

Murtaza Sameen Junejo; Assistant Professor: *Concepts, Design, Literature search, Data acquisition, Data analysis, Statistical analysis,*

Manuscript preparation, Manuscript editing, Manuscript review.

Amna Manzoor; Associate Professor: *Literature search, Manuscript editing, Manuscript review.*

Saadullah; Associate Professor: *Design, Data analysis, Manuscript review.*

Fariha Taimur; Associate Professor: *Concepts, Manuscript editing, Manuscript review.*

Sumeya Ali Khan; Assistant Professor: *Manuscript editing, Manuscript review.*

