

# Radiological Findings in Chest CT Scan for Patients with Ocular T.B.



Mohammed Suhail Najm Al-Salam<sup>1</sup>, Farah Akram Mohammed Al-Mahdawi<sup>2</sup>, Zainab Nadom Hamoodi Al-Khafaji<sup>3</sup>  
<sup>1-3</sup>Department of Surgery, College of Medicine, Mustansiriyah University, Baghdad, Iraq

## ABSTRACT

**Purpose:** To identify radiological findings on chest CT scan for patients with ocular tuberculosis (TB) that may provide an important aiding diagnostic tool in diagnosing those patients.

**Study Design:** Descriptive observational study.

**Place and Duration of Study:** Ibn Al-Haitham Eye Teaching Hospital from October 2022 to September 2024.

**Methods:** This study included 32 patients with tuberculosis associated uveitis. Patients were classified into four subtypes of uveitis based on clinical examination and anatomical location of inflammation into anterior, intermediate, posterior and panuveitis. Each patient underwent a high-resolution chest CT scan to assess for radiological signs commonly associated with pulmonary tuberculosis. Patients with known causes of pulmonary diseases or surgeries other than tuberculosis were excluded from the study.

**Results:** Out of 32 patients, 24 were males (75%) and 8 were females (25%), with mean age of 50.56±14.04 years. Chest CT indicated that 66.7% of male and 37.5% of female exhibited abnormal findings suggestive of pulmonary TB. Twenty-two patients had chronic panuveitis, 7 had intermediate uveitis, and 3 had anterior granulomatous uveitis. Chronic Tuberculous panuveitis demonstrated the highest frequency of positive pulmonary findings on CT (63.6%), followed by tubercular intermediate uveitis cases (42.9%). Conversely, no positive pulmonary findings were identified among patients with chronic granulomatous tubercular anterior uveitis.

**Conclusion:** Chest CT scan should be considered in the work up for patients with suspected tuberculous uveitis. Chronic TB panuveitis and tubercular intermediate uveitis showed a higher frequency of abnormal chest CT findings, particularly fibrotic lung scarring and nodules.

**Keywords:** Tuberculosis, Ocular tuberculosis, Panuveitis, Pulmonary Fibrosis.

**How to Cite this Article:** Al-Salam MSN, Al-Mahdawi FAM, Al-Khafaji ZNH. Radiological Findings in Chest CT Scan for Patients with Ocular T.B.2025;41(3):258-264. **Doi:** 10.36351/pjo.v41i3.2052

---

*Correspondence: Zainab Nadom Hamoodi Al-Khafaji  
Department of Surgery, College of Medicine, Mustansiriyah  
University, Baghdad, Iraq  
Email: znhamoodi80@uomustansiriyah.edu.iq*

---

*Received: March 11, 2025*

*Revised: June 16, 2025*

*Accepted: June 23, 2025*

## INTRODUCTION

Tuberculosis (TB) is a significant health problem worldwide, ranking as the ninth most common cause of death with nine million people affected annually and causing two million deaths globally.<sup>1</sup> In Erbil in

northern Iraq, the incidence of TB increased steadily from 2012 to 2016.<sup>2</sup> In 2012, the rate was 16:100,000 inhabitants, rising to 21.7:100,000 by 2016, with a marked increase in 2015 and 2016. This growth reflects a rise in reported cases from 121 in 2012 to 173 in 2016.<sup>2,3</sup>

Tuberculosis is an important cause of infectious uveitis in both endemic and nonendemic regions.<sup>4,5</sup> In Alshakarchi study in Iraq, the most frequent infectious causes were toxoplasmosis (13.8%) and presumed ocular tuberculosis (11.4%), while the most common non-infectious causes included Vogt-Koyanagi-Harada disease (12.3%) and Behçet's disease (8.2%).<sup>6</sup> Intraocular TB is a great imitator of numerous uveitis

conditions and should be included in the differential diagnosis for any form of intraocular inflammation.<sup>7</sup> Ocular inflammation may manifest unilaterally or bilaterally, with the inflammation in one eye potentially commencing months or even years prior to that in the other eye. TB is a known cause of anterior, intermediate, posterior and panuveitis. TB uveitis is often chronic, granulomatous, and associated with broad based synechia.<sup>8</sup> Iris nodules or granulomas are more frequently identified. TB intermediate uveitis is often associated with more extensive anterior segment involvement. TB posterior uveitis may include focal, multifocal, and serpiginous choroiditis.<sup>8</sup> TB retinal vasculitis is frequently ischemic in nature and may present with proliferative retinopathy such as recurrent vitreous haemorrhage, rubeosis iridis and neovascular glaucoma.<sup>9,10</sup>

The diagnosis of TB uveitis is often challenging largely because of the diverse clinical presentations associated with it and the difficulties in isolating the causative pathogen. The diagnosis of TB uveitis is often labelled presumptive and falls largely on finding clinical picture compatible with TB uveitis along with investigations providing evidence of latent TB infection such as tuberculin skin test and interferon gamma release assay (IGRA) and radiological tests such as chest x ray and CT scans providing evidence of possible, often old, previous pulmonary TB infection.<sup>11</sup>

Given the rising incidence of tuberculosis, and its established role as a significant cause of infectious uveitis, identifying possible pulmonary TB findings on CT scans is critical for improved diagnosis and treatment. This study aims to find findings suggestive of TB on chest CT scans that help in providing an important aiding diagnostic tool for patients with suspected TB uveitis.

## METHODS

A descriptive observational study was conducted on 32 patients with tuberculosis associated uveitis who presented to Ibn Al-Haitham Eye Teaching Hospital from October 2022 to September 2024 and registered on 12<sup>th</sup> September 2022 with the ethical review board [Ref. No. 142]. This study was conducted in compliance with ethical standards and approved by the ethical committee of College of Medicine University of Baghdad After excluding all other causes of uveitis, patients with confirmed evidence of tuberculosis-

related uveitis, evidence of latent TB infection (positive Interferon gamma assay test) and a documented response to anti-TB therapy were included. Patients were classified into four subtypes of uveitis based on clinical examination and anatomical location of the inflammation into anterior, intermediate, posterior and panuveitis. Each patient underwent a high-resolution chest CT scan to assess radiological signs commonly associated with pulmonary TB. The CT images were evaluated by radiologists who were blinded to the uveitis subtype to maintain objectivity. With the aim of excluding other causes, patients with known causes of pulmonary diseases or surgeries other than TB were carefully excluded from the study.

The collected data included demographic variables, uveitis subtype, and radiological findings (fibrotic scar, nodule, bronchiectasis, and mediastinal nodule). This information was recorded in a structured data collection form to ensure consistency. Statistical analysis was conducted using SPSS V.26. Descriptive statistics were calculated, including mean and standard deviation for continuous variables like age, and counts and percentages for categorical variables such as gender and uveitis subtype.

The association between uveitis type and CT findings was evaluated using chi-square tests for categorical variables. A p-value of <0.05 was considered significant. Written informed consent was obtained from all participants before enrolment in the study. Participants were informed about the study's purpose, procedures, and their right to confidentiality and to withdraw from the study at any time without penalty.

## RESULTS

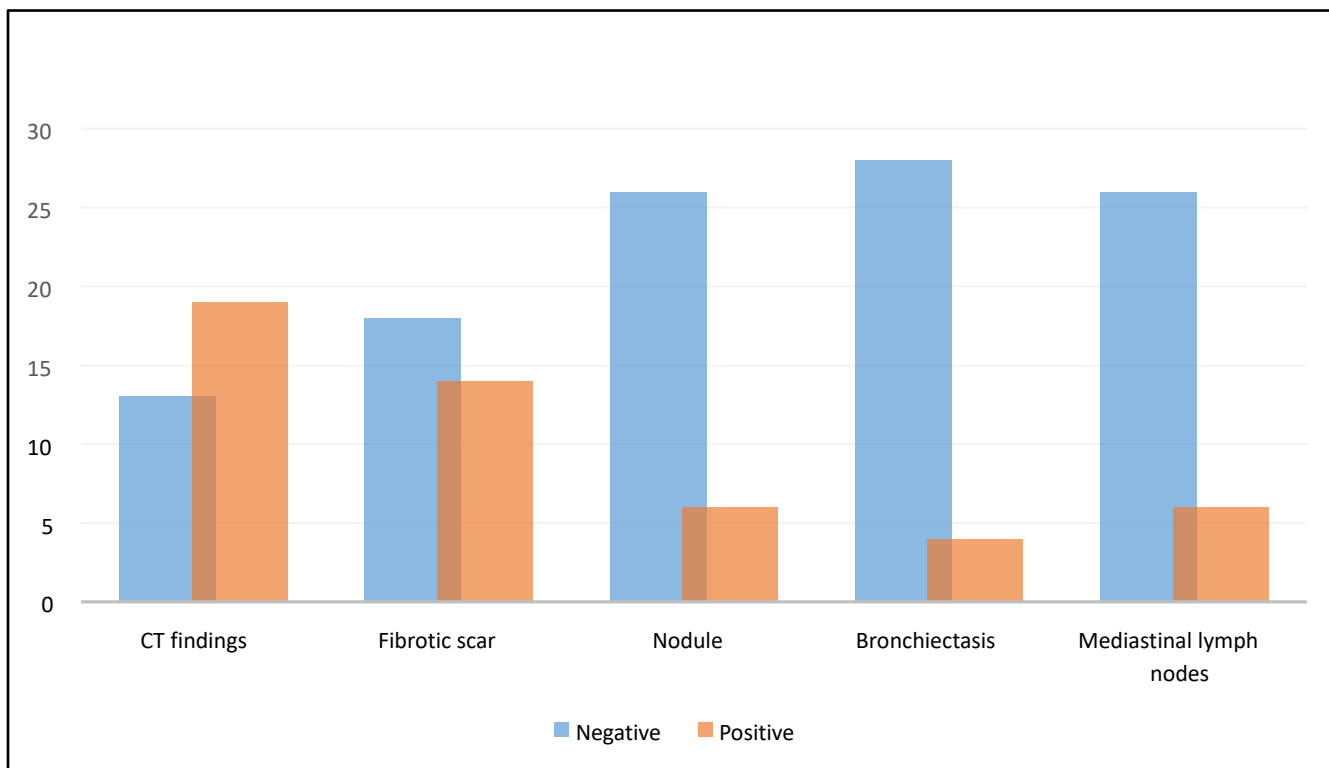
The study included 32 patients, comprising 24 males (75%) and 8 females (25%), with a mean age of 50.56±14.04 years. Analysis of CT results indicated that 66.7% of male participants and 37.5% of female participants exhibited abnormal findings on chest CT scans, though this gender difference did not reach statistical significance ( $p = 0.146$ ). Twenty-two patients had chronic panuveitis, 7 had intermediate uveitis, and 3 had granulomatous anterior uveitis (Table 1). The most common radiological abnormality in this study was fibrotic lung scar in 14 patients followed by calcified and non-calcified pulmonary nodule and mediastinal nodule in 6 patients, details

can be shown in Figure 1.

A detailed examination of pulmonary findings across uveitis types indicated marked variability in the presence of abnormalities. Chronic panuveitis cases demonstrated the highest frequency of positive pulmonary findings on CT (63.6%), followed by intermediate uveitis cases (42.9%). Conversely, no

**Table1:** Types of TB uveitis in males and females.

Uveitis Type	Male (Count & %)	Female (Count & %)
Chronic Panuveitis	17 (70.8%)	5 (62.5%)
Intermediate Uveitis	5 (20.8%)	2 (25.0%)
Chronic Granulomatous Anterior Uveitis	2 (8.3%)	1 (12.5%)



**Figure 1:** Chest CT findings in patients with TB uveitis.

**Table 2:** Radiological findings in different TB uveitis types.

Finding	Subcategory	Chronic Panuveitis (Count & %)	Intermediate Uveitis (Count & %)	Chronic Granulomatous Anterior Uveitis (Count & %)
CT findings	Normal	6 (27.3%)	4 (57.1%)	3 (100.0%)
	Abnormal	16 (72.7%)	3 (42.9%)	0 (0.0%)
Fibrotic Scar	Negative	11 (50.0%)	4 (57.1%)	3 (100.0%)
	Positive	11 (50.0%)	3 (42.9%)	0 (0.0%)
Nodule	Negative	17 (77.3%)	6 (85.7%)	3 (100.0%)
	Positive	5 (22.7%)	1 (14.3%)	0 (0.0%)
Bronchiectasis	Negative	18 (81.8%)	7 (100.0%)	3 (100.0%)
	Positive	4 (18.2%)	0 (0.0%)	0 (0.0%)
Mediastinal Nodule	Normal	17 (77.3%)	6 (85.7%)	3 (100.0%)
	Abnormal	5 (22.7%)	1 (14.3%)	0 (0.0%)

positive pulmonary findings were identified among the patients with chronic granulomatous anterior uveitis.

This disparity in pulmonary CT findings across uveitis subtypes reached statistical significance ( $p = 0.033$ ),

suggesting a potential association between certain uveitis subtypes and pulmonary manifestations as shown in Table 2.

Further differentiation of CT findings revealed distinct patterns of abnormalities among the various uveitis types. Chronic panuveitis was associated with a high frequency of abnormal CT results, including fibrotic scarring in 50% and nodular lesions in 22.7%. Intermediate uveitis cases also displayed a significant proportion of abnormal CT findings, with 42.9% of cases presenting with fibrotic scarring and 14.3% showing nodules. In contrast, patients with chronic granulomatous anterior uveitis consistently demonstrated normal CT findings, with no evidence of fibrotic scarring, nodules, or other abnormalities.

## DISCUSSION

Diagnosis of TB uveitis poses a diagnostic challenge with most cases labelled as presumed TB uveitis as obtaining conclusive intraocular evidence of tuberculosis via polymerase chain reaction (PCR) necessitates an invasive vitrectomy. However, this approach is limited by low sensitivity and the possibility of false-positive results.<sup>12,13</sup>

The collaborative ocular tuberculosis study (COTS-1) diagnostic criteria for TB uveitis require both the presence of clinical signs suggestive of TB uveitis and the exclusion of other potential causes.<sup>14</sup> Patients must show confirmed evidence of *Mycobacterium tuberculosis* through microscopy, PCR, or extra pulmonary TB findings, or have supportive tests, such as a positive Mantoux or interferon gamma release assay, or evidence of active or healed lesions on chest radiography.<sup>15,16</sup>

CT scan is the most sensitive modality for detecting radiological findings in pulmonary TB with the capability to detect hilar lymphadenopathy, parenchymal and airway diseases.<sup>11</sup> Radiological assessments for systemic TB (active or inactive) were not particularly helpful by using chest X-rays alone; however, the adoption of chest CT scans has enhanced their effectiveness.<sup>17</sup> For these reasons this study was conducted to evaluate CT scan findings of the chest in patients with TB uveitis.

In our study, analysis of chest CT results indicated that 59.3% of patients (66.7% of male participants and 37.5% of female participants) exhibited abnormal findings on chest CT scans that are suggestive of

tuberculosis. The most common radiological abnormality in this study was fibrotic lung scar in 14 patients followed by calcified and non-calcified pulmonary nodule and mediastinal nodule each present in 6 patients. This finding further supports the evidence that TB uveitis might occur secondary to primary TB infection occurring outside the eye in which the lungs account for the majority of these cases.<sup>18,19</sup>

One study aimed to assess the efficacy of high-resolution computerized tomography (HRCT) of the chest in diagnosing granulomatous uveitis. It involved 58 patients with varying types of uveitis. HRCT identified tuberculosis in 81% of cases, sarcoidosis in 8.6%, and normal findings in 10.3%. This observational study demonstrated that HRCT is a pivotal diagnostic tool in the management of granulomatous uveitis.<sup>17</sup> The most common clinical presentation was posterior uveitis, affecting 31.4% of cases, followed by intermediate uveitis 20% and anterior uveitis 19%. The least common was panuveitis, found in 12.3% of cases.

Like this study, HRCT findings suggestive of tuberculosis were most prevalent in posterior uveitis cases (46.8%), followed by anterior uveitis (23.4%), pan uveitis (18.5%), and only a few cases of intermediate uveitis (11.3%).<sup>20</sup>

In another study involving 29 Eales's disease patients, HRCT chest scans identified tuberculosis-related abnormalities in 51.7% of cases. Notable findings included calcified nodules, mediastinal hilar lymphadenopathy, and minor parenchymal soft tissue lesions. These results show the effectiveness of HRCT in detecting signs of pulmonary tuberculosis in patients with Eales's disease, demonstrating its critical diagnostic role.<sup>21</sup>

## CONCLUSION

The study highlights the importance of chest CT as a diagnostic tool in identifying possible radiological findings suggestive of pulmonary TB in patients with presumed TB uveitis. Chronic TB panuveitis and tubercular intermediate uveitis showed a higher prevalence of abnormal CT findings, particularly fibrotic lung scarring and nodules.

**Funding:** This study was not funded by any organization.

**Patient's Consent:** Researchers followed the guide lines set forth in the Declaration of Helsinki.

**Conflict of Interest:** Authors declared no conflict of interest.

**Ethical Approval:** The study was approved by the Institutional review board/Ethical review board (**Ref No. 142**).

## REFERENCES

1. **Bagchi S.** WHO's Global Tuberculosis Report 2022. *Lancet Microbe.* 2023;**4(1)**:e20. Doi: 10.1016/S2666-5247(22)00359-7.
2. **Balaky STJ, Saniotis A, Mawlood AH, Hussein AM, Shabila NP.** Incidence and geographical distribution of tuberculosis disease in Erbil city, Iraq. *Braz J Microbiol.* 2022;**53(2)**:519-523. Doi: 10.1007/s42770-022-00717-1.
3. **Dheda K, Perumal T, Moultrie H, Perumal R, Esmail A, Scott AJ, et al.** The intersecting pandemics of tuberculosis and COVID-19: population-level and patient-level impact, clinical presentation, and corrective interventions. *Lancet Respir Med.* 2022;**10(6)**:603-622. Doi: 10.1016/S2213-2600(22)00092-3.
4. **Tsui JK, Poon SHL, Fung NSK.** Ocular manifestations and diagnosis of tuberculosis involving the uvea: a case series. *Trop Dis Travel Med Vaccines.* 2023;**9(1)**:20. Doi: 10.1186/s40794-023-00205-w.
5. **Taylor JW, Wright GEL, Lim LL, Denholm JT.** A systemic review of the utility of antituberculosis therapy for presumed tuberculous uveitis. *BMC Infect Dis.* 2025;**25(1)**:112. Doi: 10.1186/s12879-024-10288-1.
6. **Al-Shakarchi FI.** Pattern of uveitis at a referral center in Iraq. *Middle East Afr J Ophthalmol.* 2014;**21(4)**:291-295. Doi: 10.4103/0974-9233.142263.
7. **Xu H, Xu M, Chen F, Chen H, Du W, Yu J.** Detection of Mycobacterium tuberculosis DNA in intraocular fluid of 11 suspected tuberculous uveitis patients by multiplex PCR. *BMC Ophthalmol.* 2025;**25(1)**:7. Doi: 10.1186/s12886-025-03843-0.
8. **Schlaen A, Montoya J, Heredia M, Inchauspe S, Dodds EM.** Infectious causes of retinal vasculitis: Causes, presentation, differentiation, and therapy. *Ophthalmologica.* 2025:1-46. Doi: 10.1159/000545044.
9. **Kon OM, Beare N, Connell D, Damato E, Gorsuch T, Hagan G, et al.** BTS clinical statement for the diagnosis and management of ocular tuberculosis. *BMJ Open Respir Res.* 2022;**9(1)**:e001225. Doi: 10.1136/bmjresp-2022-001225.
10. **Proia AD, Wroblewski KJ.** Non-neoplastic Pathology of the Uveal Tract. In: **Albert DM, Miller JW, Azar DT, Young LH, editors.** *Albert and Jakobiec's Principles and Practice of Ophthalmology.* Cham: Springer International Publishing; 2022. p. 6131-6221. Doi: 10.1007/978-3-030-42634-7\_130
11. **Putera I, Schrijver B, Ten Berge JCEM, Gupta V, La Distia Nora R, Agrawal R, et al.** The immune response in tubercular uveitis and its implications for treatment: From anti-tubercular treatment to host-directed therapies. *Prog Retin Eye Res.* 2023;**95**:101189. Doi: 10.1016/j.preteyeres.2023.101189.
12. **Shukla D, Kalliath J, Dhawan A.** Tubercular Retinal Vasculitis: Diagnostic Dilemma and Management Strategies. *Clin Ophthalmol.* 2021;**15**:4681-4688. Doi: 10.2147/OPHTH.S284613.
13. **La Distia Nora R, Putera I, Khalisha DF, Septiana I, Sitompul R.** The diagnostic value of polymerase chain reaction for ocular tuberculosis diagnosis in relation to antitubercular therapy response: a meta-analysis. *Int J Infect Dis.* 2021;**110**:394-402. Doi: 10.1016/j.ijid.2021.07.075.
14. **La Distia Nora R, Putera I, Schrijver B, Singh G, Bakker M, Riasanti M, et al.** Ocular Tuberculosis Diagnosis Through Biomarkers: Clinical Relevance of Serum C1q and Whole Blood Interferon Gene Signature Score. *Ocul Immunol Inflamm.* 2025;**33(1)**:113-124. Doi: 10.1080/09273948.2024.2368670.
15. **Rees CE, Swift BM, Haldar P.** State-of-the-art detection of Mycobacterium tuberculosis in blood during tuberculosis infection using phage technology. *Int J Infect Dis.* 2024;**141S**:106991. Doi: 10.1016/j.ijid.2024.106991.
16. **Bindayna KM, Al-Salman J.** Infections of the respiratory system. In: **Bindayna KM, Al-Salman J, editors.** *Problem-Based Learning Approach in Microbiology. Developments in Microbiology.* Academic Press; 2023. p. 187-254. Doi: 10.1016/B978-0-323-95092-3.00006-8
17. **Rea G, Sperandeo M, Lieto R, Bocchino M, Quarato CMI, Feragalli B, et al.** Chest Imaging in the Diagnosis and Management of Pulmonary Tuberculosis: The Complementary Role of Thoracic Ultrasound. *Front Med (Lausanne).* 2021;**8**:753821. Doi: 10.3389/fmed.2021.753821.
18. **Helal RS, Attia S, Al-Baker ZM, Al-Shweiki S, Abu Sbeit R, Abukhattab M, et al.** Spectrum of Presumed Tubercular Uveitis in a Referral Eye Clinic in Qatar. *Ocul Immunol Inflamm.* 2025;**33(1)**:105-112. Doi: 10.1080/09273948.2024.2368668.

19. **Zhang YK, Guan Y, Zhao J, Wang LF.** Diagnosis of tuberculous uveitis by the macrogenome of intraocular fluid: A case report and review of the literature. *World J Clin Cases.* 2023;**11(14)**:3248-3255. Doi: 10.12998/wjcc.v11.i14.3248.
20. **Boshra MM, Stylianidies A, Agrawal H.** Presumed ocular tuberculosis in a developed country: a descriptive retrospective analysis of patients from a tertiary health care centre in the United Kingdom. *J Egypt Ophthalmol Soc.* 2025;**118(1)**:27-30. Doi:10.4103/ejos.ejos\_32\_24
21. **Gupta P, Biswas J.** Further evidence of the association of latent Mycobacterium tuberculosis in Eales' disease. *Int Ophthalmol.* 2021;**41(3)**:901-906. Doi: 10.1007/s10792-020-01645-5.

### Authors Designation and Contribution

Mohammed Suhail Najm Al-Salam; Consultant Ophthalmologist: *Concepts, Design, Data Acquisition, Data Analysis, Statistical Analysis, Manuscript Review.*

Farah Akram Mohammed Al-Mahdawi; Consultant Ophthalmologist: *Concepts, Design, Literature Search, Data Analysis, Manuscript Preparation, Manuscript Editing, Manuscript Review.*

Zainab Nadom Hamoodi Al-Khafaji; Consultant Ophthalmologist: *Concepts, Literature Search, Statistical Analysis, Manuscript Preparation, Manuscript Editing, Manuscript.*

