

Comparing Diagnostic Accuracy of MRW and RNFL in Detection of Glaucoma

PJO – Official Journal of Ophthalmological Society of Pakistan
Volume 2023;39(4):295-300.
Doi: 10.36351/pjo.v39i4.1704



This work is licensed under a **Creative Commons Attribution-Non-Commercial 4.0 International License**.

Nazish Khan¹, Munira Shakir², Sahira Wasim³
Salman Azmi⁴, Shakir Zafar⁵
^{1,2,3,4}Liaquat National Hospital, Karachi, ⁵United Medical & Dental College, Karachi

ABSTRACT

Purpose: To compare diagnostic accuracy of Bruch's membrane opening minimum rim width (BMO-MRW) and Retinal Nerve Fibre Layer (RNFL) in detection of glaucoma taking cup to disc ratio as gold standard.

Study Design: Descriptive observational.

Place and Duration of Study: Liaquat National Hospital, Karachi from September 2017 to February 2018.

Methods: Total 344 participants including healthy and glaucoma suspect (according to the cup disc ratio or high intra ocular pressure more than 21 mmHg) were included. They were evaluated to compare diagnostic accuracy of MRW and RNFL taking cup to disc ratio as gold standard. Spectral domain OCT was performed. Sensitivity, specificity, and diagnostic accuracy of MRW and RNFL were calculated keeping cup-disc finding as gold standard.

Results: Mean Cup to Disk Ratio was 0.54 ± 0.10 . Total 97.4% cases were diagnosed to have Glaucoma by Cup to Disk Ratio, 84.3% cases were diagnosed with Glaucoma by RNFL and 94.8% cases by MRW. By RNFL, 288 patients were true positive and 7 patients were true negative. Sensitivity, Specificity, and accuracy were 86.0%, 77.8%, and 85.7% respectively. The results showed that by MRW, 324 patients were true positive, and 7 patients were true negative. Sensitivity, Specificity, and accuracy were 96.7%, 77.8%, and 96.2% respectively.

Conclusion: The sensitivity of RNFL for diagnosis of glaucoma is higher than MRW. While the specificity of both RNFL and MRW was similar.

Key Words: Diagnosis, Mean Rim Width, Retinal Nerve Fibre Layer, Glaucoma.

How to Cite this Article: Khan N, Shakir M, Wasim S, Azmi S, Zafar S. Comparing Diagnostic Accuracy of MRW and RNFL in Detection of Glaucoma.

*Correspondence: Sahira Wasim
Liaquat National Hospital, Karachi
Email: sahirawasim@gmail.com*

*Received: July 30, 2023
Accepted: September 13, 2023*

INTRODUCTION

One of the irreversible causes of blindness in the world is Glaucoma.¹ There has been significant improvement in early diagnosis of glaucoma with the invention of automated computerized software for the analysis and detection of retinal nerve fibre layer and optic nerve head pathology.² Glaucoma affects retinal ganglion

cells (RGC) that are complex large neurons with dendrites making synapses in the inner plexiform layer (IPL) with amacrine and bipolar cells of retina. Ganglion cell layer (GCL) is composed of RGCs cell bodies while their axons constitute retinal nerve fibre layer (RNFL) which merge at optic nerve head (ONH) to form neuro-retinal rim.³ Optical coherence tomography (OCT) was first described in 1991.⁴ Early attempts had lower reproducibility. However, for the assessment of optic nerve head another parameter including neuro-retinal rim and Bruch's membrane opening minimum rim width (BMO-MRW) were proposed. Distance between inner opening of BMO to the internal limiting membrane (ILM) was measured. In contrast to ophthalmoscopy, it is geometrically

more stable and provides more accurate evaluation of neuro retinal rim.⁵

Glaucoma Premium Module Edition software is spectral-domain optical coherence tomography (SD-OCT; Heidelberg Engineering GmbH) which includes new inception of measurement of neuro-retinal rim, anatomically and geometrically, taking new topographic parameter of the ONH-BMO-MRW into account. BMO-MRW provides advantage for the orientation of OHN by correctly representing the amount of neuro retinal rim tissue. Furthermore, the acquired BMO-MRW data are regionalized relative to the axis that lie between BMO and fovea of the eye allowing its accurate analyses.⁶ Studies depict at 95% specificity of both RNFL and MRW, the sensitivity of RNFL and MRW is 70% and 81% respectively.⁷

This study aimed to compare diagnostic accuracy of RNFL and MRW using glaucoma premium modules software on the basis of sensitivity and specificity taking cup to disc ratio as gold standard. Early detection of glaucoma is important to start treatment before irreversible loss to the optic nerve head fibres occurs which leads to blindness.

METHODS

This descriptive cross sectional study was conducted in Liaquat National Hospital, Karachi from September 2020 to February 2021 after approval from institutional review board. With prevalence of glaucoma as 69.03%, sample size was calculated by taking sensitivity of MRW as 81.7% at fixed specificity of 95.7% and confidence interval of 95% with desired precision of 5%. The total sample size was 344. Non-probability consecutive sampling was used for this study.

Study participants included healthy patients and glaucoma suspect (according to cup to disc ratio or high intra ocular pressure of more than 21 mmHg) attending the eye clinic at Liaquat National Hospital, Karachi. Participants of either gender and age between 25 to 60 years were included. Persons with history of any ocular trauma, previous ocular surgery e.g. trabeculectomy, vitrectomy affecting retina, obvious ocular pathology e.g. retinopathy related with diabetes and age related macular degeneration and neurological diseases including multiple sclerosis that affect retinal structure and normal visual function pathway were excluded. Data was collected on a pre-designed proforma. Informed consent was taken. After detailed

history, examination was performed including refraction with best corrected visual acuity, slit-lamp examination, dilated Fundoscopy and tonometry with Goldmann Applanation. Experienced technician performed imaging and diagnostic procedure included spectral domain OCT using Spectral GMPE software version 6.0 and OCT machine Heidelberg engineering 2.0. Both eyes were eligible for the study. Confounders were controlled by strictly following inclusion and exclusion criteria. Effect modifiers were diabetes and hypertension. The outcome variable was glaucoma (positive or negative) on the basis of MRW, RNFL and optic disc cupping. Data were compiled and analysed using SPSS Version 25. Frequency and percentage were computed for qualitative variables like gender, hypertension, diabetes mellitus, cup to disk ratio, MRW and RNFL. Mean±SD were calculated for quantitative variable i.e. age and cup to disk ratio. Diagnostic Accuracy was computed for MRW and RNFL keeping cup to disk finding as a gold standard. Post stratification specificity, sensitivity, positive predictive values (PPV) and negative predictive value (NPV) along with diagnostic accuracy of MRW and RNFL were calculated. The stratification was done for gender and age to see the effect of these modifiers on outcome i.e. accuracy.

RESULTS

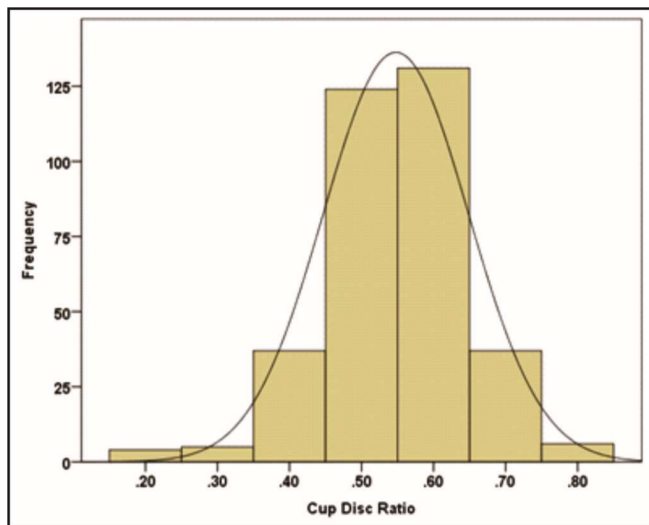
Total 344 patients of either gender with age between 25 to 60 years meeting inclusion criteria were evaluated to compare diagnostic accuracy of MRW and RNFL in detection of glaucoma taking cup disc ratio as gold standard. The results showed 220 (64%) male and 124 (36%) females. Mean age of the study participants was 55.37 ± 4.23 years. The age was further stratified in two groups. There were 15% patients with less than or equal to 50 years and 85% were more than 50 years of age. There were 9.9% diabetic and 72.4% were hypertensive. Mean Cup to Disk Ratio was 0.54 ± 0.10 .

There were 97.4% cases who were diagnosed with Glaucoma using Cup to Disk Ratio and 84.3% cases were diagnosed with Glaucoma by RNFL and 94.8% cases were diagnosed by MRW. Sensitivity, Specificity, Predictive values and diagnostic accuracy of MRW and RNFL in detection of glaucoma taking cup to disc ratio as gold standard were calculated.

The results showed that by RNFL, 288 patients were true positive and 7 were negative with sensitivity,

specificity, PPV, NPV and accuracy values of 86.0%, 77.8%, 99.3%, 13.0%, and 85.7% respectively.

accuracy values which were 96.7%, 77.8%, 99.4%, 38.9%, and 96.2% respectively (Table 1).



Graph 1: Histogram Presenting Distribution of Cup Disc Ratio (n=344)

As far as MRW is concerned, the results showed that by MRW, 324 were correctly diagnosed as true positive patient, 7 were diagnosed true negative patients, with sensitivity, specificity, PPV, NPV and

Table 1: Diagnostic accuracy of RNFL and MRW for diagnosis of glaucoma taking cup to disk ratio as gold standard.

		Cup Disk Ratio		Total
		Positive	Negative	
RNFL	Positive	288(99.3)	2(0.7)	290(84.3)
	Negative	47(87)	7(13)	54(15.7)
Sensitivity	Specificity	PPV	NPV	Accuracy
86.00%	77.80%	99.30%	13.00%	85.70%
MRW	Positive	324(99.4)	2(0.6)	326(94.8)
	Negative	11(61.1)	7(38.9)	18(5.2)
Sensitivity	Specificity	PPV	NPV	Accuracy
96.70%	77.80%	99.40%	38.90%	96.20%

The MRW stratification according to gender, age, Diabetes Mellitus, and hypertension was done and sensitivity, specificity, and diagnostic accuracy were also calculated, Detailed results are presented in Table 2.

The RNFL stratification according to gender, age, Diabetes Mellitus, and hypertension was done and sensitivity, specificity, and diagnostic accuracy were also calculated, Detailed results are presented from Table 03.

Table 2: Diagnostic accuracy of MRW for glaucoma with respect to baseline characteristics taking cup to disk ratio as gold standard.

Variables		Sensitivity	Specificity	PPV	NPV	Accuracy
Age	≤50 years	100.00%	100%	100%	100.00%	100.00%
	> 50 years	96.10%	71.40%	99.30%	31.20%	95.50%
Gender	Male	95.80%	83.30%	99.50%	35.70%	95.40%
	Female	98.30%	66.70%	99.20%	50.00%	97.50%
Diabetes	Yes	100.00%	99.70%	96.90%	100.00%	97.05%
	No	96.40%	83.30%	99.70%	31.30%	96.10%
Hypertension	Yes	96.80%	0.00%	99.60%	0.00%	96.30%
	No	96.50%	77.80%	99.40%	38.90%	95.70%

Table 3: Diagnostic accuracy of RNFL for diagnosis of glaucoma with respect to baseline characteristics taking cup disk ratio as gold standard.

Variables		Sensitivity	Specificity	PPV	NPV	Accuracy
Age	≤50 yrs	90.20%	100%	100%	28.60%	90.56%
	> 50 yrs	85.20%	71.40%	99.20%	10.60%	84.87%
Gender	Male	84.60%	83.30%	99.50%	13.20%	85.50%
	Female	88.40%	66.70%	99.10%	12.50%	87.90%
Diabetes	Yes	35.50%	100.00%	100.00%	13.00%	41.10%
	No	91.10%	66.70%	99.30%	12.90%	90.60%
Hypertension	Yes	99.20%	100.00%	100.00%	33.30%	99.10%
	No	48.30%	75.00%	95.50%	11.70%	50.50%

DISCUSSION

Glaucoma remains world's second most significant cause of irreversible blindness. Early diagnosis is the key to control its progression and eventual damage to the optic nerve fibres.⁸ An increasing number of technologies have been introduced over time to assist in early screening for glaucoma. Retinal ganglion cells along with their axonal damage is the characteristic feature of glaucoma pathology. It not only leads to remodelling but also atrophy of the optic nerve head manifesting as narrowing of the neuro-retinal rim, excavation of nerve and lamina cribrosa appearing as lamellar dot sign.

In 1979, Harry Quigley and William R. Green, demonstrated that the optic disc cupping was caused by loss of axons of ganglion cells.⁹ Longitudinal evaluation of optic disc longitudinal diameter at different time points helps to identify progressive damage even in the absence of clearly defined visual field loss.¹⁰ RNFL measurement through SD-OCT is also helpful in detection of pre-perimetric stage of glaucoma.¹¹

Glaucoma Module Premium Edition is a software which allows enhanced 3-Dimensional Versus 2-Dimensional diagnostic capability of Neuro Retinal Rim parameters using SD-OCT. Investigators have proposed an anatomically and geometrically accurate neuro retinal rim parameters, which is one aspect of an OCT-based paradigm change in the clinical assessment of the optic nerve head. BMO-MRW parameter allows measurement of rim from outer border of neuro retinal rim, that is, BMO, which represents maximum optic nerve head aperture through which retinal ganglion cell axons pass. It provides accurate geometrical measurement, which measures minimum rim width from BMO to the internal limiting membrane not along or parallel to the fixed plane of the optic disc margin or BMO. Recent publications considered that BMO-MRW has a higher diagnostic and powerful association with visual field as compared to conventional rim parameters.¹² Better assessment of optic nerve depth is provided by SD-OCT. Automated delineation software allows accuracy to delineate the anatomical landmark that is termination of Bruch's membrane BMO.¹³ It provides superior assessment in myopia with tiled oblique insertion. Identifying glaucoma in myopic patient by both global and sectoral BMO-MRW showed better diagnostic performance than RNFL thickness. Both BMO-MRW and RNFL thickness had lower

sensitivity, but for myopia exceeding 6D these parameters showed higher sensitivity and specificity at 85% and 81%, respectively. Overall diagnostic performance of imaging devices is not affected by the structural abnormalities in myopic eyes.⁷

It was also noted that sectoral analysis of 6 sectors, for BMO-MRW performed better than RNFL thickness.¹³ The difference between glaucomatous eyes and control myopic eyes was better appreciated in inferotemporal sector while inferonasal sector showed statistical significance.¹³ One of the studies showed that mean RNFL thickness had sensitivity and specificity of 82% and 96% respectively.¹⁴ It is important to take into consideration age of the patient when evaluating outcome of RNFL thickness because progressive deterioration is seen in the values of RNFL thickness with increasing age.¹⁴ Kim et al. showed that in cases of early glaucoma, OCT detected RNFL defects while standard automated perimetry results were within normal limits.¹⁵ According to Leung et al. RNFL defects with the progression of glaucoma were picked up by OCT. The measurement of RNFL defect can provide an additional dimension for the measurement of glaucoma.¹⁶ The work of Blumenthal indicated that RNFL measurements by OCT were reproducible for both normal and glaucomatous eyes.¹⁷ Parikh et al. showed Stratus OCT had 75% sensitivity and 89.6% specificity for the diagnosis of early glaucoma with positive and negative predictive values of 75% and 98% respectively.¹⁸

Pieroth et al, studied clinically detectable RNFL defects using clinical examination, red free photography, or automated Visual fields in 19 glaucoma patients and 14 controls using OCT. They establish the results with sensitivity of 65% only and specificity of 81%.¹⁹ Significant difference was found between measured RNFL thickness in glaucoma patients group and normal subjects in Guides et al study.²⁰ In our study, we observed 77.8% specificity of both RNFL and MRW and sensitivity of RNFL and MRW as 86.0% and 96.7% respectively.

Limitation of this study was small sample size and single-centre study preventing generalization of results.

CONCLUSION

The sensitivity of RNFL measurements for diagnosis of glaucoma is higher than MRW. While the specificity of both RNFL and MRW was equal.

Bruch's membrane opening MRW is similar to RNFL thickness for the identification of glaucoma in myopic eyes and offers a valuable diagnostic tool for patients with glaucoma with myopic optic discs.

Conflict of Interest: Authors declared no conflict of interest.

Ethical Approval: The study was approved by the Institutional review board/Ethical review board (App No. 0714-2019-LNH-ERC).

REFERENCES

- Fan KC, Tsikata E, Khoueir Z, Simavli H, Guo R, DeLuna R, et al.** Enhanced diagnostic capability for glaucoma of 3-dimensional versus 2-dimensional neuroretinal rim parameters using spectral domain optical coherence tomography. *J. Glaucoma*, 2017;**26(5)**:450. Doi: 10.1097/IJG.0000000000000647
- Chien JL, Ghassibi MP, Patthanathamrongkasem T, Abumasmah R, Rosman MS, Skaat A, et al.** Glaucoma diagnostic capability of global and regional measurements of isolated ganglion cell layer and inner plexiform layer. *J. Glaucoma*, 2017;**26(3)**:208-215. Doi: 10.1097/IJG.0000000000000572
- Akman A.** Role of optical coherence tomography in glaucoma. *Optical Coherence Tomography in Glaucoma: A Practical Guide*, 2018:13-25. Doi: 10.1007/978-3-319-94905-5_3
- Gmeiner JM, Schrems WA, Mardin CY, Laemmer R, Kruse FE, Schrems-Hoesl LM.** Comparison of Bruch's membrane opening minimum rim width and peripapillary retinal nerve fiber layer thickness in early glaucoma assessment. *Invest Ophthalmol Vis Sci*. 2016;**57(9)**:575-584. Doi: 10.1167/iovs.15-18906
- Chauhan BC, Danthurebandara VM, Sharpe GP, Demirel S, Girkin CA, Mardin CY, et al.** Bruch's membrane opening minimum rim width and retinal nerve fiber layer thickness in a normal white population: a multicenter study. *Ophthalmol*. 2015;**122(9)**:1786-1794. Doi: 10.1016/j.ophtha.2015.06.001
- Toshev AP, Lamparter J, Pfeiffer N, Hoffmann EM.** Bruch's membrane opening-minimum rim width assessment with spectral-domain optical coherence tomography performs better than confocal scanning laser ophthalmoscopy in discriminating early glaucoma patients from control subjects. *J Glaucoma*. 2017;**26(1)**:27-33. Doi: 10.1097/IJG.0000000000000532
- Chauhan BC, O'Leary N, Al-Mobarak FA, Reis AS, Yang H, Sharpe GP, et al.** Enhanced detection of open-angle glaucoma with an anatomically accurate optical coherence tomography-derived neuroretinal rim parameter. *Ophthalmol*. 2013;**120(3)**:535-543. Doi: 10.1016/j.ophtha.2012.09.055
- Sarhan A, Rokne J, Alhaji R.** Glaucoma detection using image processing techniques: A literature review. *Computerized Medical Imaging and Graphics*, 2019;**78**:101657. Doi: 10.1007/978-3-030-32587-9_13
- Quigley HA, Green WR.** The histology of human glaucoma cupping and optic nerve damage: clinicopathologic correlation in 21 eyes. *Ophthalmol*. 1979;**86(10)**:1803-1827. Doi: 10.1016/S0161-6420(79)35338-6
- Stagg BC, Medeiros FA.** A comparison of OCT parameters in identifying glaucoma damage in eyes suspected of having glaucoma. *Ophthalmol. Glaucoma*, 2020;**3(2)**:90-96. Doi: 10.1016/j.ogla.2019.11.008
- Yusof AMZ, Othman O, Tang SF, Hassan MR, Din NM.** Diagnostic evaluation of optical coherence tomography parameters in normal, preperimetric and perimetric glaucoma patients. *Int J Ophthalmol*. 2022;**15(11)**:1782-1790. Doi: 10.18240/ijo.2022.11.08.
- Li R, Wang X, Wei Y, Fang Y, Tian T, Kang L, et al.** Diagnostic capability of different morphological parameters for primary open-angle glaucoma in the Chinese population. *BMC Ophthalmol*. 2021;**21(1)**:151. Doi: 10.1186/s12886-021-01906-6.
- Almobarak FA, O'Leary N, Reis AS, Sharpe GP, Hutchison DM, Nicoleta MT, et al.** Automated segmentation of optic nerve head structures with optical coherence tomography. *Invest Ophthalmol Vis Sci*. 2014;**55(2)**:1161-1168. Doi: 10.1167/iovs.13-13310
- Gondal TM, Qazi ZU, Jamil AZ, Jamil MH.** Accuracy of the retinal nerve fiber layer measurements by stratus optical coherence tomography for perimetric glaucoma. *J Coll Physicians Surg Pak*. 2011;**21(12)**:749-752.
- Kim TW, Zangwill LM, Bowd C, Sample PA, Shah N, Weinreb RN.** Retinal nerve fiber layer damage as assessed by optical coherence tomography in eyes with a visual field defect detected by frequency doubling technology perimetry but not by standard automated perimetry. *Ophthalmol*. 2007;**114(6)**:1053-1057. Doi: 10.1016/j.ophtha.2006.09.015
- Leung CK, Choi N, Weinreb RN, Liu S, Ye C, Liu L, et al.** Retinal nerve fiber layer imaging with spectral-domain optical coherence tomography: pattern of RNFL defects in glaucoma. *Ophthalmol*. 2010;**117(12)**:2337-2344. Doi: 10.1016/j.ophtha.2010.04.002

17. **Blumenthal EZ, Williams JM, Weinreb RN, Girkin CA, Berry CC, Zangwill LM.** Reproducibility of nerve fiber layer thickness measurements by use of optical coherence tomography. *Ophthalmol.* 2000;**107(12)**:2278-2282.
Doi: 10.1016/S0161-6420(00)00341-9
18. **Parikh RS, Parikh S, Sekhar GC, Kumar RS, Prabakaran S, Babu JG, et al.** Diagnostic capability of optical coherence tomography (Stratus OCT 3) in early glaucoma. *Ophthalmol.* 2007;**114(12)**:2238-2243.
Doi: 10.1016/j.ophtha.2007.03.005
19. **Pieroth L, Schuman JS, Hertzmark E, Hee MR, Wilkins JR, Coker J, et al.** Evaluation of focal defects of the nerve fiber layer using optical coherence tomography. *Ophthalmol.* 1999;**106(3)**:570-579.
Doi: 10.1016/S0161-6420(99)90118-5
20. **Guedes V, Schuman JS, Hertzmark E, Wollstein G, Correnti A, Mancini R, et al.** Optical coherence tomography measurement of macular and nerve fiber layer thickness in normal and glaucomatous human eyes. *Ophthalmol.* 2003;**110(1)**:177-189.
Doi: 10.1016/S0161-6420(02)01564-6

Authors' Designation and Contribution

Nazish Khan; Consultant Ophthalmologist: *Concepts, Design, Literature Search, Data Acquisition, Data Analysis, Manuscript Preparation.*

Munira Shakir; Professor: *Design, Manuscript Editing, Manuscript Review.*

Sahira Wasim; Consultant Ophthalmologist: *Literature Search, Statistical Analysis, Manuscript Preparation, Manuscript Editing, Manuscript Review.*

Salman Azmi; Resident: *Literature Search, Manuscript Editing.*

Shakir Zafar; Professor: *Literature Search Statistical Analysis, Manuscript Review.*

